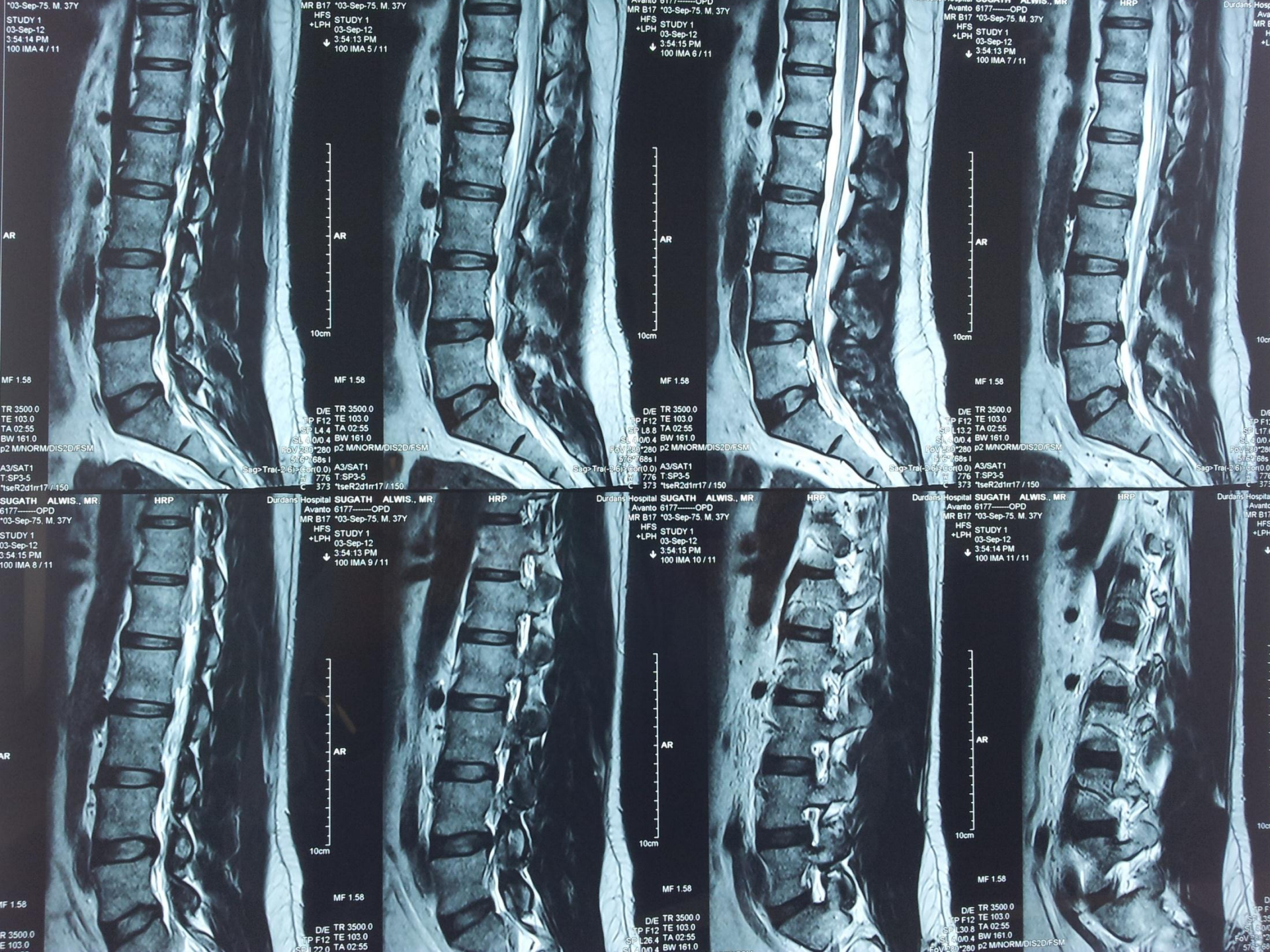
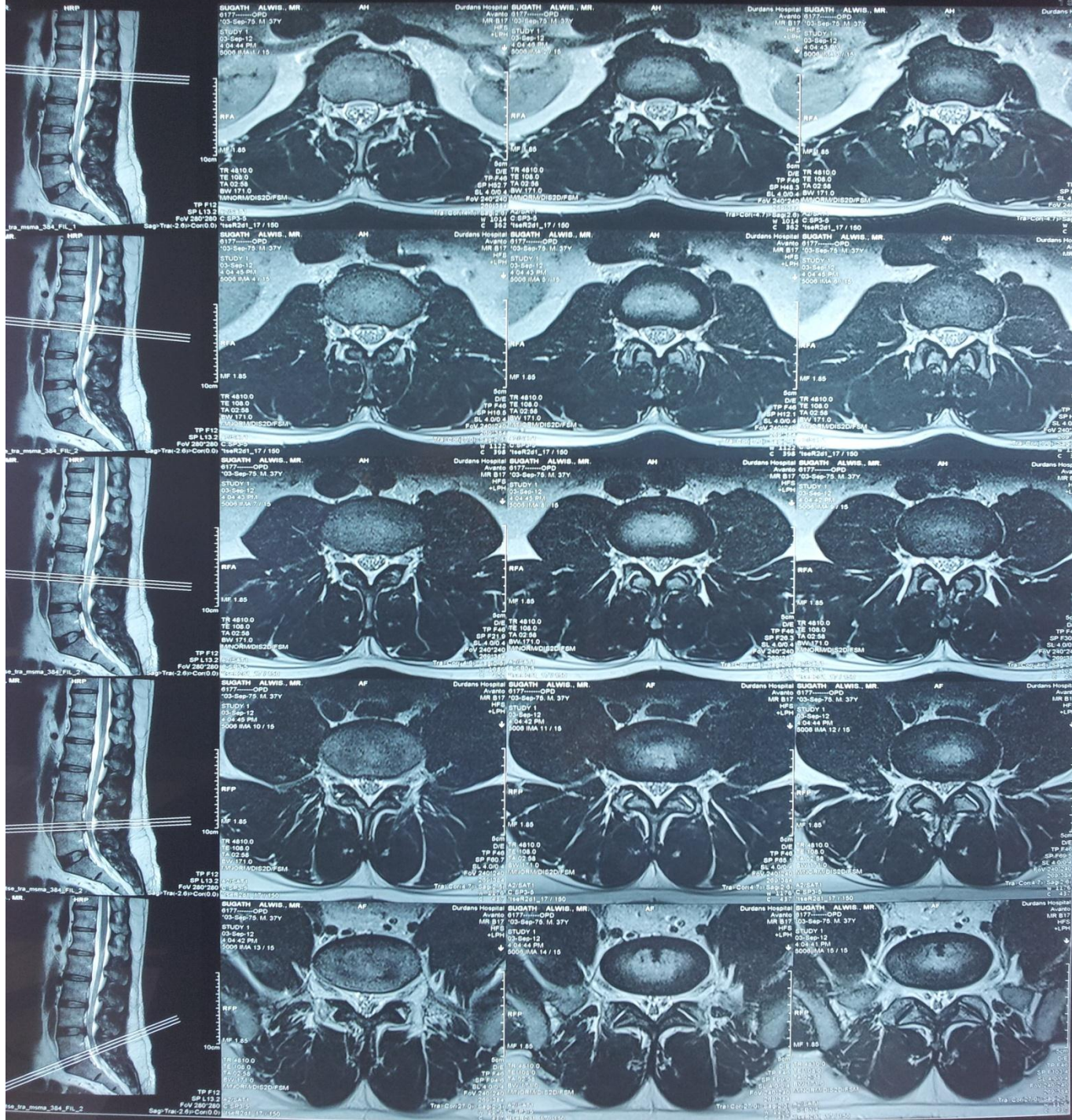


- 37yrs
- M
- Lower back pain
- Left L5 radiculopathy

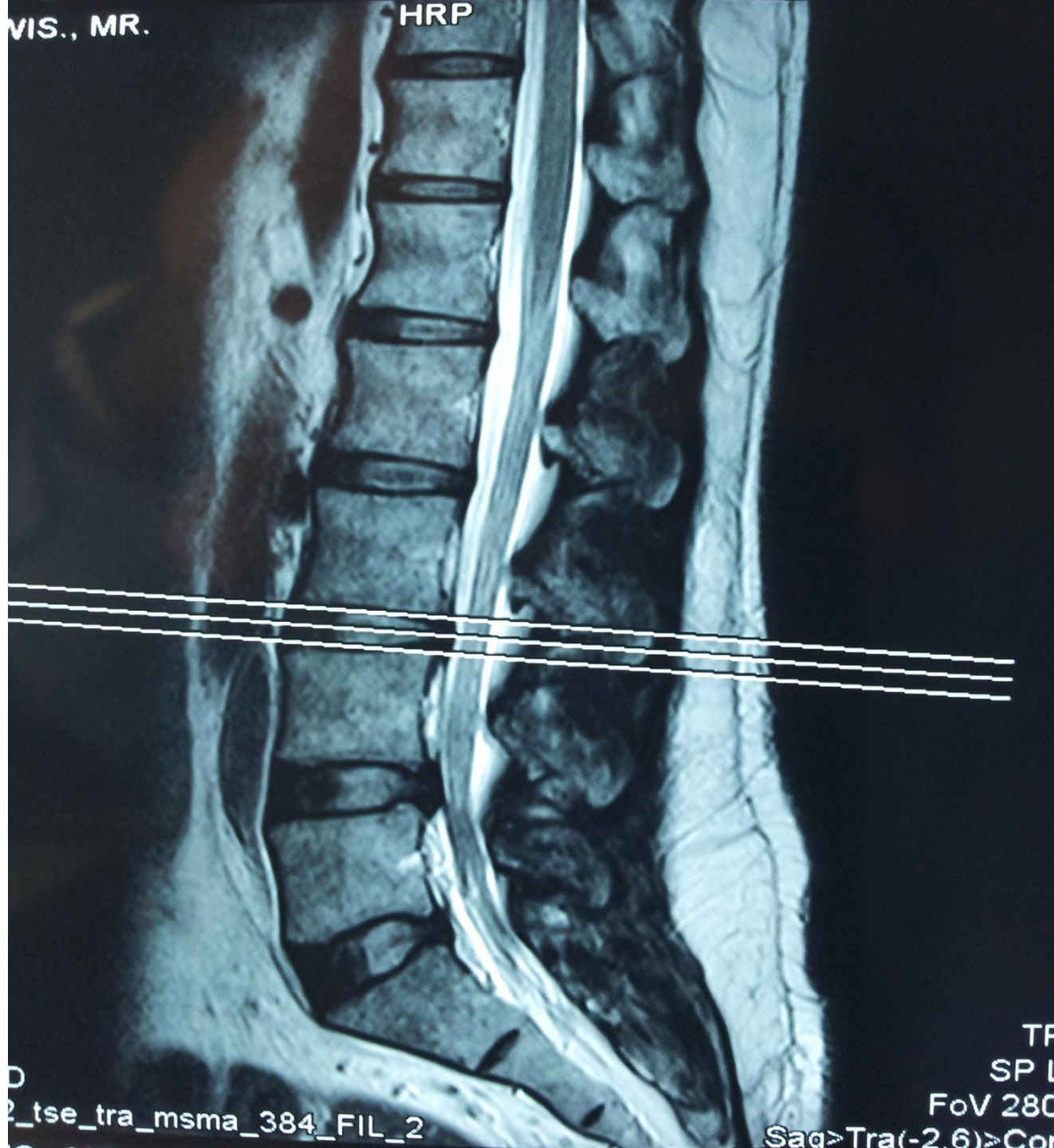- Ix. – Lumbar spine MRI





VIS., MR.

HRP



D
2_tse_tra_msma_384_FIL_2

TR
SP L
FoV 280
Sag>Tra(-2.6)>Cor

03-Sep-12
5012 IMA 6 / 1

AR

1



10cm

p2 M/NORM/DIS2D
PosDisp: [8] t2_tse_tra_msma_384

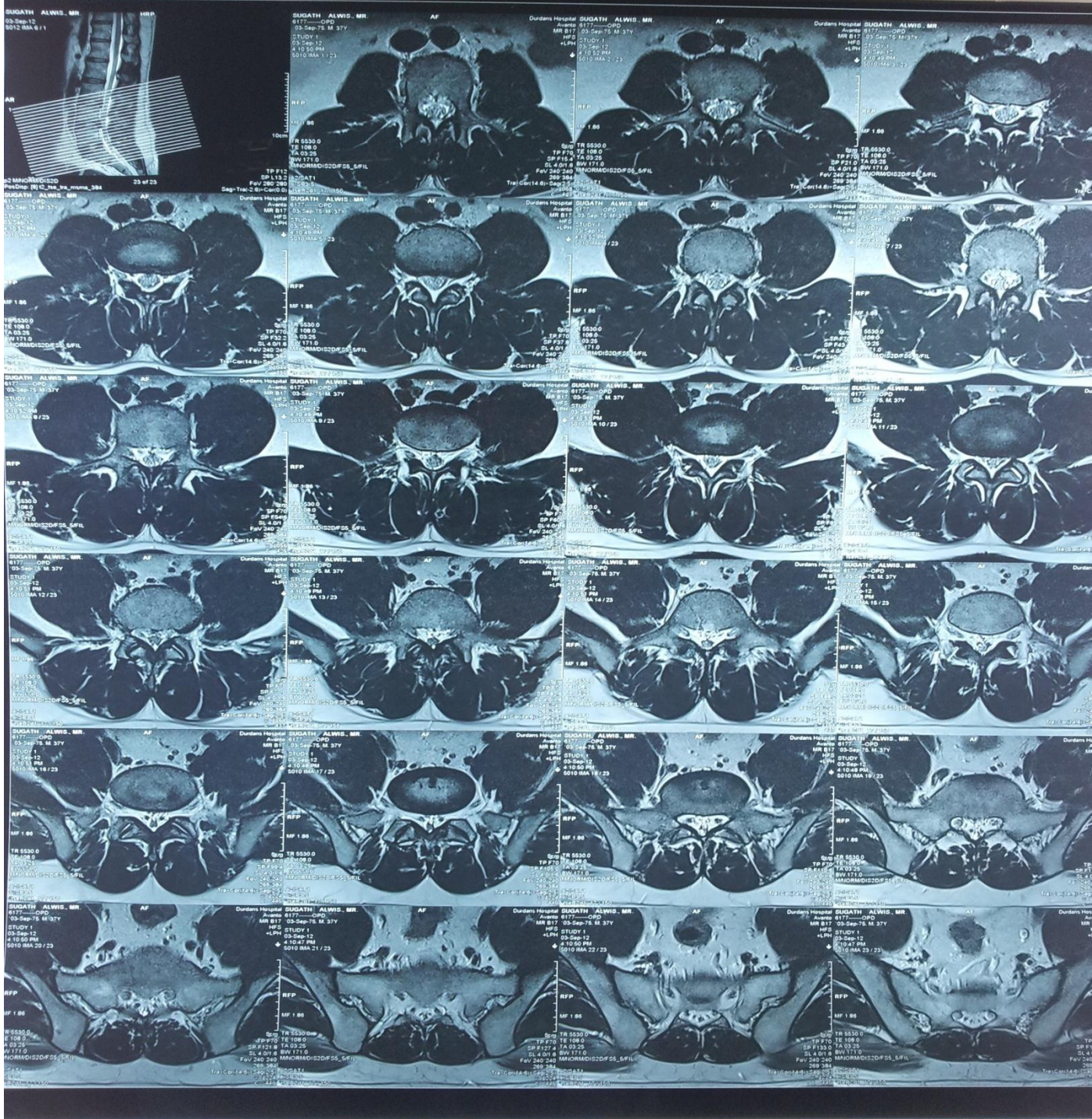
23 of 23

TP F12
SP L13.2
FoV 280*280
Sag>Tra(-2.6)>Cor(0.0)

SUGATH ALWIS., MR.

AF

Durdans Hospital
Avanto



Collaboration & Co-operation

